

800 Pasquinelli Dr. Westmont, IL 60559 USA

toll-free: 800.556.0349

sales@thomasmedical.com

## MILLER ADVANCE CATHETER

### INDICATIONS

For administering contrast media or saline during hysterosalpingography and saline infusion sonohysterogram procedures to detect uterine pathology such as polyps, fibroids, adhesions, or endometrial thickening, and/ or to examine the patency of the fallopian tubes.

### CONTRAINDICATIONS:

Suspected infection, suspected pregnancy, profuse bleeding, or sexually transmitted disease.

### PRECAUTIONS:

Do not exceed the recommended balloon inflation volume (1.5 cc for the 5 Fr catheter) or the balloon may burst. The use of OIL-BASED contrast media such as ethyl esters may interact with the balloon of the catheter, causing possible balloon rupture. The use of aqueous contrast media is recommended.

### ADVERSE EVENTS:

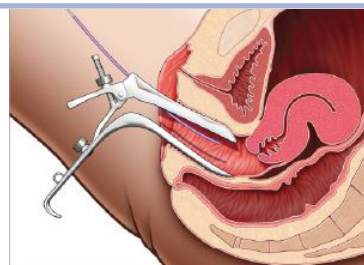
Some patients may have a hypersensitivity to contrast media.

### INSTRUCTIONS FOR USE:

1. Remove catheter from pouch.
2. Remove and discard the protective sleeve.
3. Attach a syringe with either contrast media or saline (not supplied) to the luer connector of the injection line. Inject contrast media or saline through the catheter to remove air. Advance the insertion sheath so that the distal end of the catheter protrudes slightly from the distal end of the sheath.

**Figure 1**

Advance the sheath and catheter together.

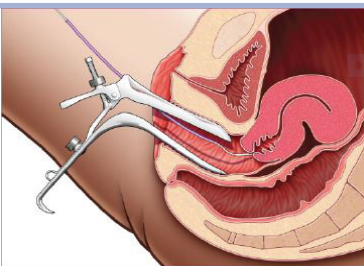


4. View the cervix and advance the sheath and catheter together into the cervix. ( See Figure 1)
5. While holding the sheath, advance the catheter through the cervical canal and into the uterus.

5.A. Follow these steps when the catheter is blocked by the uterus. (See figures 2-5)

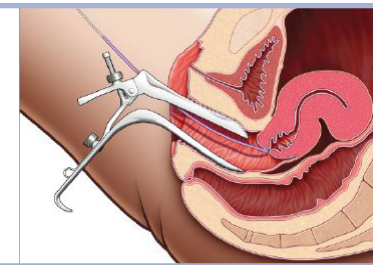
**Figure 2**

If entry is blocked by the uterus...



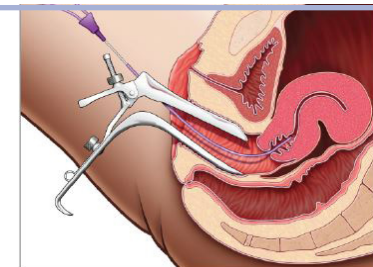
**Figure 3**

Bring the catheter back into the sheath.



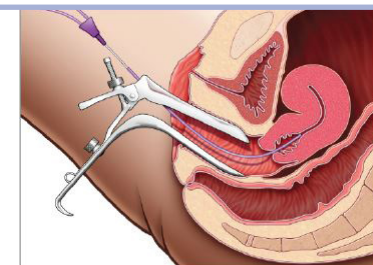
**Figure 4**

Advance the sheath so that it naturally follows the cervical canal through the endocervix and into the uterus.



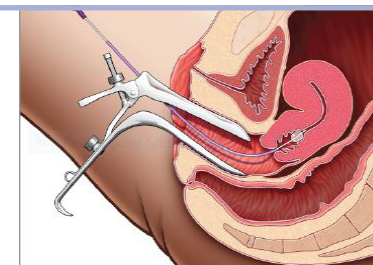
**Figure 5**

Whether the uterus is anteflexed or retroflexed, the flexible sheath can advance into position.



**Figure 6**

Draw sheath back to external os and inflate the balloon.



6. Open the stopcock and slowly inflate the balloon with either air or saline up to 1.5cc for the 5F catheter. ( See Figure 6)
7. Close the stopcock, allowing the balloon to remain inflated. Gently withdraw catheter so balloon will rest against the internal os.
8. Inject contrast media or saline into the uterus and complete the examination.
9. Open the stopcock to deflate the balloon. withdraw the catheter.

MANUFACTURED BY:  
Thomas Medical, Inc.  
800 Pasquinelli Dr. Westmont,  
IL 60559 USA  
Telephone: (800) 556-0349  
Fax: (888) 411-3754



STERILE

MADE IN USA

MICTRU5A-IF2